

CLINICAL INVESTIGATION

Retroclavicular vs supraclavicular brachial plexus block for distal upper limb surgery: a randomised, controlled, single-blinded trial

Sina Grape¹, Amit Pawa², Eric Weber¹ and Eric Albrecht^{3,*}

¹Department of Anaesthesia, Valais Hospital, Sion, Switzerland, ²Department of Anaesthesia, Guy's & St Thomas' NHS Foundation Trust, London, UK and ³Department of Anaesthesia, Lausanne University Hospital, Lausanne, Switzerland

*Corresponding author. E-mail: eric.albrecht@chuv.ch

Previously presented in part at the Annual Meeting of the European Society of Regional Anaesthesia and Pain Medicine, Dublin, Ireland, September 12–15, 2018.

Abstract

Background: Regional anaesthesia for upper limb surgery is routinely performed with brachial plexus blocks. A retroclavicular brachial plexus block has recently been described, but has not been adequately compared with another approach. This randomised controlled single-blinded trial tested the hypothesis that the retroclavicular approach, when compared with the supraclavicular approach, would increase the success rate.

Methods: One hundred and twenty ASA physical status 1–3 patients undergoing distal upper limb surgery were randomised to receive an ultrasound-guided retroclavicular or supraclavicular brachial plexus block with 30 mL of a 1:1 mixture of mepivacaine 1% and ropivacaine 0.5%, using a single-injection technique without needle tip repositioning. The primary outcome was block success rate 30 min after local anaesthetic injection, defined as a composite score of 14 of 16 points, inclusive of sensory and motor components. Secondary outcomes included needling time, time to first opioid request, oxycodone consumption, and pain scores (numeric rating scale, 0–10) at 24 h postoperatively.

Results: Success rates were 98.3% [95% confidence interval (CI): 90.8%, 99.9%] and 98.3% [95% CI: 90.9%, 99.9%] in the supraclavicular and retroclavicular groups, respectively ($P=0.99$). The mean needling time was reduced in the supraclavicular group [supraclavicular: 5.0 (95% CI: 4.7, 5.4) min; retroclavicular: 6.0 (95% CI: 5.4, 6.6) min; $P=0.006$]. The mean time to first opioid request was similar between groups [supraclavicular: 439 (95% CI: 399, 479) min; retroclavicular: 447 (95% CI: 397, 498) min; $P=0.19$] as were oxycodone consumption [supraclavicular: 10.0 (95% CI: 6.5, 13.5) mg; retroclavicular: 7.9 (95% CI: 4.8, 11.0) mg; $P=0.80$] and pain scores at 24 h postoperatively [supraclavicular: 1.2 (95% CI: 2.1, 2.7); retroclavicular: 1.5 (95% CI: 1.6, 2.4); $P=0.09$].

Conclusions: Ultrasound-guided retroclavicular and supraclavicular brachial plexus blocks share identical success rates, while providing similar pain relief. Reduced needling time in the supraclavicular approach is not clinically relevant.

Clinical trial registration: NCT02641613.

Keywords: brachial plexus; nerve block; postoperative analgesia; regional anaesthesia; ultrasound-guided

Editorial decision: 02 December 2018; **Accepted:** 2 December 2018

© 2019 British Journal of Anaesthesia. Published by Elsevier Ltd. All rights reserved.
For Permissions, please email: permissions@elsevier.com

Editor's key points

- Retroclavicular brachial plexus block is a new approach with several reported advantages, although it has not been properly compared with a traditional approach.
- Success rates of supraclavicular and retroclavicular brachial plexus blocks with a single-injection technique are more than 98% when performed by experienced physicians.
- Retroclavicular brachial plexus block is associated with a potential risk of nerve injury or vascular puncture when advancing the needle blindly behind the clavicle.

Regional anaesthesia for distal upper limb surgery is routinely performed with supraclavicular, infraclavicular, or axillary brachial plexus blocks.¹ In the authors' experience, the supraclavicular block is the method of choice in a busy ambulatory centre because of its average onset time of <10 min.²

Recently, a new ultrasound-guided approach to the brachial plexus has been reported on a case series of 50 patients, named the retroclavicular block.³ This approach consists of inserting the needle in the supraclavicular fossa, behind the clavicle, in-plane in a paramedian sagittal plane cephalo-caudad direction until the needle tip is positioned behind the axillary artery.^{3,4} This technique has recently been termed the RAPTIR block (retroclavicular approach to the infraclavicular region).⁵ Reported advantages of the retroclavicular block over the traditional approach to the infraclavicular area are short procedure time, better needle visualisation, low patient discomfort, high patient satisfaction, and optimal site for catheter insertion.^{3,5} This paradigm has been confirmed in a recent trial where authors compared the retroclavicular with the infraclavicular brachial plexus block and took the visibility of the needle as a primary outcome,⁶ without investigating pain outcomes.

As the retroclavicular approach has never been compared with an alternative more established ultrasound-guided approach, we performed this randomised controlled single-blinded trial and tested the hypothesis that the retroclavicular brachial plexus block would increase the success rate when compared with a supraclavicular procedure.

Methods

We followed the recommended process described in the Consolidated Standards of Reporting Trials statement.⁷

Recruitment and randomisation

This trial was approved by the Ethics Committee of the state of Valais (Commission cantonale valaisanne d'éthique médicale, protocol number CCVEM 038/15) and was prospectively registered on clinicaltrials.gov (NCT02641613). All patients aged 18–85 yr, ASA physical status 1–3, who were undergoing elective forearm or hand surgery between January 2017 and April 2018 at the Hospital of Valais were eligible to participate in this study. Exclusion criteria included existing neurological deficit in the upper limb, contraindications to peripheral nerve block (e.g. allergy to local anaesthetics, coagulopathy, infection in the area), and pregnancy. After providing written

informed consent, participating patients were randomly allocated on the day of surgery to either the supraclavicular or the retroclavicular brachial plexus groups, using a computer-generated randomisation table in aggregates of 10. Assignments were concealed in a sealed opaque envelope.

Ultrasound-guided procedures

All ultrasound-guided blocks were conducted before surgery in a dedicated block procedure room by two of the authors who are experienced providers of regional anaesthesia (S.G., E.W.). Patients were positioned supine in a semi-sitting position with the head turned 45 degrees to the non-operative side, and with the ipsilateral arm placed adducted by the patient's side. ECG, pulse oximetry, and BP monitors were routinely applied, and oxygen was provided. Peripheral i.v. access was established and i.v. midazolam 1–4 mg was administered for anxiolysis and sedation as needed. The needle insertion site was prepared with a solution of chlorhexidine 2% in isopropyl alcohol 70%. Under sterile conditions, a high-frequency linear array transducer (13–6 MHz, SonoSite S-Nerve; SonoSite, Inc., Bothell, WA, USA) was used. For the supraclavicular brachial plexus block, the probe was placed firmly over the supraclavicular fossa, parallel to the clavicle to obtain a short-axis view of the divisions of the brachial plexus and the subclavian artery, lying on the first rib. After skin infiltration with lidocaine 1%, 1–3 ml, a 23-gauge 70 mm insulated block needle (Temena UPC[®], Felsberg-Gensungen, Germany) was inserted in-plane with the ultrasound beam, in a lateral-to-medial direction, until the needle tip was positioned at the junction of the first rib and subclavian artery, in the location traditionally called the 'corner pocket' (Fig. 1a).⁸ The local anaesthetic was deposited using a single-injection technique, without repositioning the needle tip, except if patients complained of paraesthesia. In the retroclavicular approach, the probe was placed below and perpendicular to the clavicle, in a paramedian sagittal plane, medial to the coracoid process, to obtain a short-axis view of the cords of the brachial plexus and the axillary vessels. The needle was then inserted in the supraclavicular fossa, approximately 1 cm posteriorly to the clavicle, and advanced in plane and strictly parallel to the ultrasound transducer. After passing the initial blind zone of about 2 cm caused by the acoustic shadow of the clavicle, the needle tip was constantly seen, until it was positioned posterior to the axillary artery (Fig. 1b). Again, a single-injection technique was adopted where the local anaesthetic was injected without needle repositioning unless paraesthesia was elicited.

All patients received 30 ml of a 1:1 mixture of mepivacaine 1% and ropivacaine 0.5%, injected in slow 5 ml increments, with intermittent aspiration, and under constant ultrasound visualisation. A volume of 30 ml was chosen, as this is the most popular volume injected in most trials included in a recent meta-analysis that investigated ultrasound-guided supraclavicular or infraclavicular brachial plexus blocks.¹ After completion of the block, patients remained fully monitored until their transfer to the operating room.

Block assessment and definition of successful block

Assessment of sensory and motor blocks was performed by one of the investigators (S.G., E.W.) 5 min after local anaesthetic injection, every 5 min, for a total duration of 30 min, following a previously published method.² Briefly, sensory block was tested in the dermatomes of the musculocutaneous

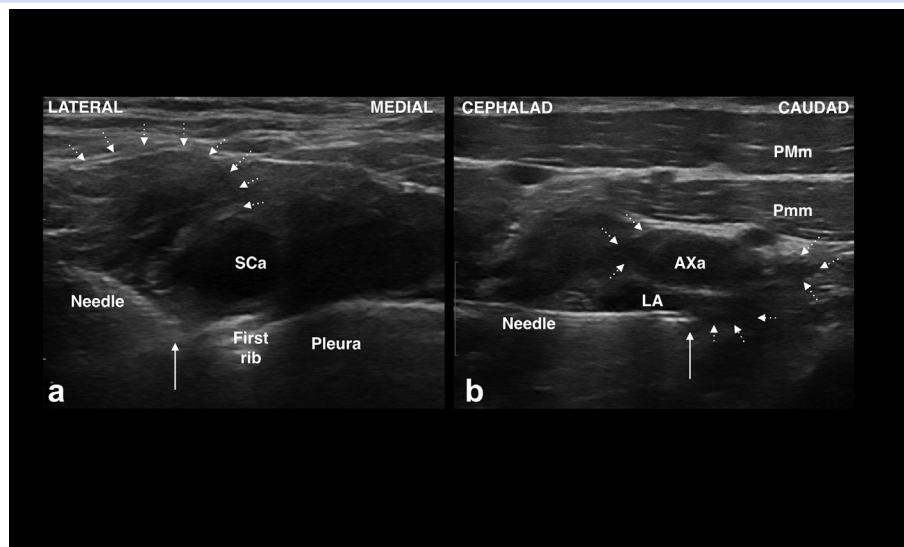


Fig 1. Ultrasound images of the two brachial plexus block techniques using a single-injection technique where the local anaesthetic was injected without needle repositioning unless paraesthesia was elicited. (a) Supraclavicular brachial plexus block: the needle tip (white arrow) was positioned at the junction of the first rib and subclavian artery ('corner pocket') in order to anaesthetise the divisions of the brachial plexus—upper limit is delimited by the dotted arrows. (b) Retroclavicular brachial plexus block: the needle tip (white arrow) was positioned posterior to the axillary artery, in order to block the lateral, posterior, and medial cords of the brachial plexus, from a cephalad to caudad direction, indicated by the dotted arrow. AXa, axillary artery; LA, local anaesthetic; PMm, pectoralis major muscle; Pmm, pectoralis minor muscle; SCa, subclavian artery.

(lateral side of the forearm), radial (lateral side of the dorsum of the hand), median (ventral side of the thumb), and ulnar nerves (ventral side of the fifth finger), using a blunt tip needle pinprick test (0, normal sensation; 1, decreased sensation; 2, no sensation). Motor block was tested using elbow flexion (musculocutaneous nerve), thumb abduction (radial nerve), thumb opposition (median nerve), and thumb adduction (ulnar nerve) with the following scale: 0, no loss of force; 1, reduced force compared with contralateral arm; 2 inability to overcome gravity). A successful block was defined as a composite score of 14 within 30 min of performing the regional procedure. In cases of block failure, the block was not repeated, and the patient had the surgery under general anaesthesia.

Intraoperative and postoperative procedures

After application of routine monitors in the operating theatre and providing oxygen, patients received conscious sedation with propofol 2–4 mg kg⁻¹ h⁻¹, on request. After completion of surgery, patients were transferred to the ward, where they received a standardised postoperative analgesic regimen consisting of oral acetaminophen 1000 mg every 4 h, and oral ibuprofen 400 mg every 8 h. Oxycodone 5 mg every 4 h was available as needed, consistent with our routine practice. Antiemetic treatment with oral ondansetron 4 mg was available as needed, as was an antihistaminergic for the treatment of pruritus.

Outcomes

The primary outcome was block success rate 30 min after local anaesthetic injection. Secondary outcomes were divided into block- and pain-related outcomes. Block-related outcomes included imaging time (defined as the time interval between

probe placement and needle insertion), needling time (defined as the time interval between needle insertion through the skin wheal and the end of local anaesthetic injection), procedure time (defined as the sum of the imaging and needling times), rates of paraesthesia, rate of vascular puncture, duration of the sensory block (defined as time from the injection of local anaesthetic to the time the patient recovered full sensation of the upper limb), and duration of the motor block (defined as time from injection of local anaesthetic to the time the patient could recover full function of the arm). Pain-related outcomes comprised pain score during block procedure [numeric rating scale (NRS), 0–10], pain scores at 2 and 24 postoperative hours (NRS out of 10), time to first opioid request (defined as the time elapsed between block procedure and first oxycodone intake), postoperative oxycodone consumption during the first 24 postoperative hours, and patient satisfaction (NRS out of 10).

After Phase II recovery, patients were discharged home with a diary and were required to write down the time to recovery from full sensation of the arm, full mobilisation of the arm, pain scores at rest and on movement, and time to first oxycodone consumption. At 24 postoperative hours, all patients received a phone call by one of the investigators to record the above-mentioned outcomes, along with presence of haematoma, persistent paraesthesia, or weakness.

As the puncture site was identical with a supraclavicular or retroclavicular brachial plexus block, patients were blinded to the group allocation, as were Phase 1 recovery nurses, ward nurses, and the person performing the statistics.

Sample size calculation

Based on a recent meta-analysis published by our group, the success rate of a supraclavicular block with a single injection

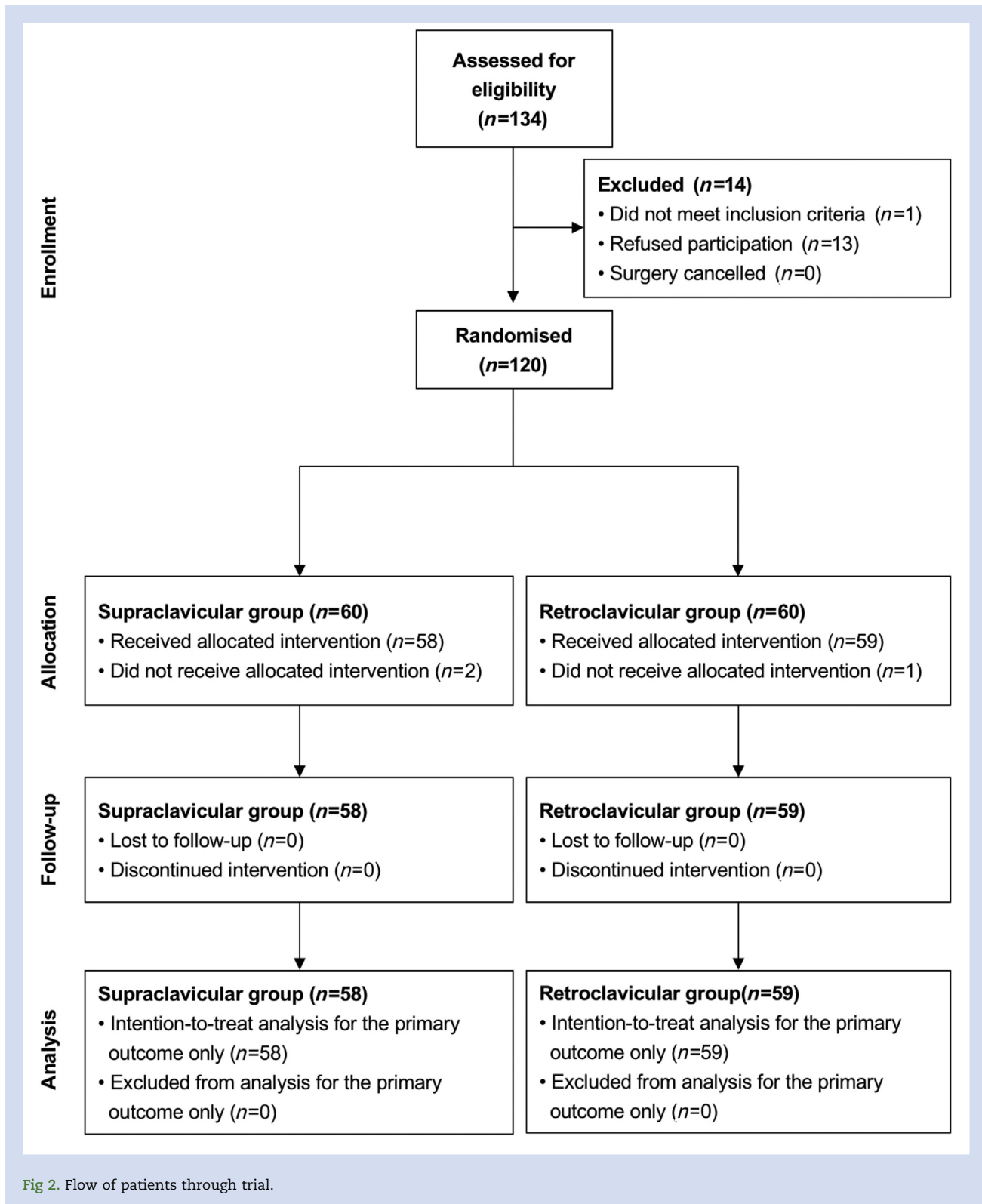


Fig 2. Flow of patients through trial.

was 86%.¹ We anticipated a 15% increase in the success rate with a retroclavicular approach. Assuming an alpha error of 0.05 and a power of 70%, we calculated that 48 patients per group were required to detect a statistically significant difference. Allowing for a 20% rate of protocol violation and dropout rate, we planned to recruit a total of 120 patients.

Statistical analysis

Data were analysed on an intention-to-treat basis. Categorical variables are presented as frequencies and continuous variables are summarised as mean values with 95% confidence intervals (95% CI). Continuous parametric and non-parametric

data were compared using the Student's *t*-test and Mann–Whitney *U*-test, respectively. Categorical and dichotomous data were compared using the Fisher's exact test or Pearson test as appropriate. Significance was considered at $P < 0.05$ based on a two-tailed probability. Statistical analysis was performed using the JMP 9 statistical package (SAS Institute, Cary, NC, USA).

Results

One hundred and twenty patients were recruited and 117 completed the protocol to measurement of the primary outcome, as three patients withdrew consent. Figure 2 describes the flow of patients during the trial and Table 1 presents patient characteristics.

Success rates were 98.3% (95% CI: 90.8%, 99.9%) and 98.3% (95% CI: 90.9%, 99.9%) in the supraclavicular and retroclavicular groups, respectively ($P = 0.99$); one patient in each group had a failed block and required general anaesthesia. There were no significant differences in onset times of sensory and motor blockade when assessed for each specific nerve; for example the mean onset time of the sensory blockade for the musculocutaneous nerve was 13.2 min (95% CI: 11.9, 14.4 min) in the supraclavicular vs 14.1 min (95% CI: 12.8, 15.5 min; $P = 0.32$), in the retroclavicular group. Likewise, mean onset times of motor blockade for the same nerve were 13.5 min (95% CI: 12.1, 14.9 min) and 15.3 min (95% CI: 13.9, 16.6 min; $P = 0.08$) in the supraclavicular and retroclavicular groups, respectively. Details of the composite score are presented in Figure 3. Among the block-related outcomes, needling time, procedure time, and duration of motor blockade were statistically different (Table 2), while pain-related outcomes were similar between groups (Table 3).

Rates of transient paraesthesia in the supraclavicular and retroclavicular groups were, respectively, 12.1% (95% CI: 5.0%, 23.3%) and 18.6% (95% CI: 9.7%, 30.9%; $P = 0.30$). Two patients from the retroclavicular group had a vascular puncture vs none in the other group, $P = 0.16$.

No patients developed hematoma, persistent paraesthesia, or weakness in the upper limb, with assessment 24 h after the procedure.

Discussion

Based on 117 patients, this single-blinded randomised controlled trial suggests that a retroclavicular brachial plexus block does not increase the success rate when compared with a supraclavicular approach. Both procedures were associated with a success rate of 98%, and additionally were equivalent in

terms of onset times of action, duration of sensory and motor blockade, pain scores, and oxycodone consumption during the first 24 postoperative hours. The statistically significant differences of the needling and procedure times with mean differences of 1 and 1.5 min in favour of the supraclavicular group do not have any clinical relevance. Similarly, the difference in duration of motor blockade does not bear any clinical impact.

In a case series of 50 patients, Charbonneau and colleagues³ reported a lower success rate (90%) despite a higher volume of mepivacaine 1% (40 ml). This difference may stem from differing expertise of the physicians who performed the blocks. Indeed, in our trial, only two consultants were involved, vs first- and second-year residents under direct supervision. The retroclavicular and supraclavicular brachial plexus blocks seem equivalent according to our results. However, in order to demonstrate formal equivalency with a limit of 4%, a *post hoc* analysis revealed that a total of 420 patients would be required with alpha and beta values of 0.05 and 0.2, respectively.

Despite the high success rate, we think that the retroclavicular brachial plexus block suffers from several drawbacks and should only be recommended for use in selected patients. First, there is a distance of 2 cm where visualisation of the needle path behind the clavicle is not possible because of the acoustic shadow of the bony structure, placing neurovascular structures at risk of being punctured. Indeed, as demonstrated recently in a cadaveric study, the suprascapular nerve and the suprascapular vein lie in the trajectory of the needle path, and the posterior cord or its components were punctured by a retroclavicular sited catheter in 50% of patients.⁹ In our study, however, no patients suffered from persistent paraesthesia or motor weakness at 24 postoperative hours. Second, in cases of vascular injury, the presence of the clavicle does not allow compression of the punctured vessels. Of note, no patients reported superficial haematoma on postoperative Day 1, including the two patients in the retroclavicular brachial plexus block who experienced vascular puncture. Third and finally, block of the musculocutaneous nerve might be delayed or even absent,³ as this nerve might leave the lateral cord before the coracoid process in 35% of patients.¹⁰ However, our results showed that each nerve, the musculocutaneous nerve included, had similar onset times of action whatever the approach adopted. That said, we would like to emphasise that, when performing the retroclavicular brachial plexus block, the practitioner should be aware of the potential risk of nerve injury or vascular puncture when advancing the needle blindly behind the clavicle.⁹

One can argue that a limitation of this study was to compare the retroclavicular with the supraclavicular brachial

Table 1 Patient characteristics and clinical data presented as mean (95% confidence interval) or absolute number as appropriate

	Supraclavicular group (n=58)	Retroclavicular group (n=59)	P-value
Gender (male/female)	33/25	37/22	0.52
Age (yr)	51 (45, 56)	46 (42, 51)	0.23
Height (cm)	172 (170, 174)	173 (171, 175)	0.54
Weight (kg)	75 (70, 80)	77 (72, 82)	0.62
BMI (kg m ⁻²)	25.2 (23.8, 26.6)	25.6 (24.2, 27.0)	0.67
ASA (1/2/3)	23/30/5	27/28/4	0.78
Duration of surgery (min)	57.8 (50.0, 65.7)	53.7 (45.6, 65.7)	0.47
Surgical location (elbow/forearm/wrist/hand)	3/2/22/31	3/3/16/37	0.64

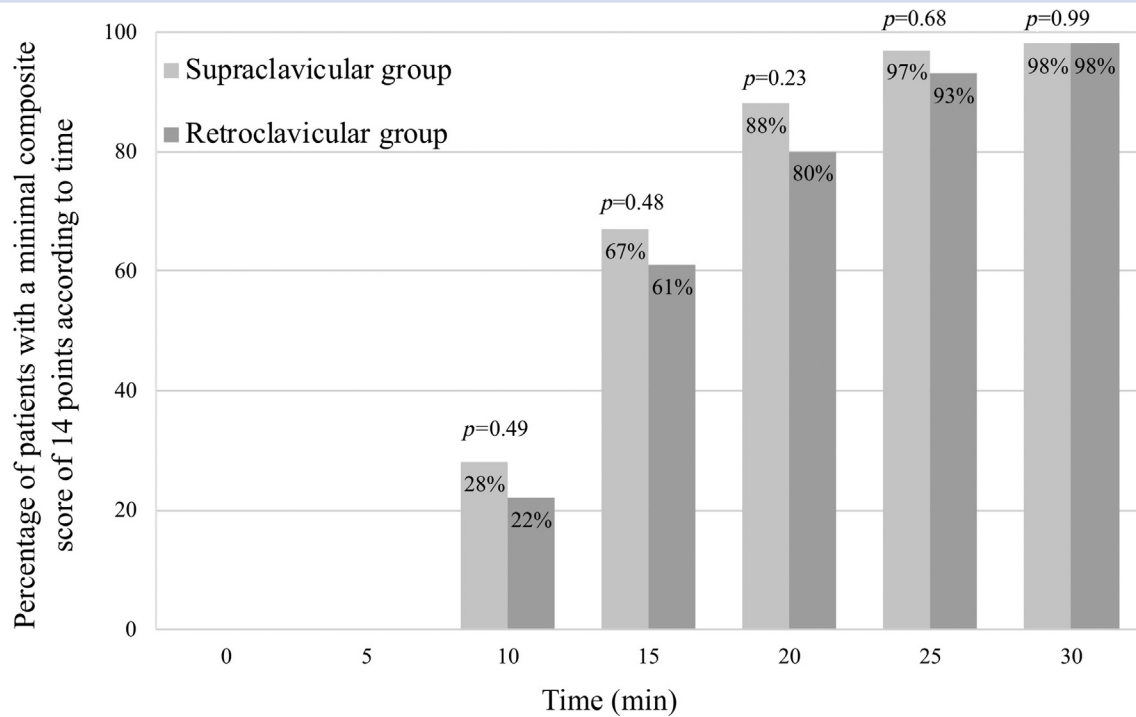


Fig 3. Percentage of patients with a minimal composite score of 14 points according to time. There was no significant difference between groups throughout the 30 min period of block assessment.

Table 2 Block-related outcomes. Data are presented as means with 95% confidence interval. NRS, numeric rating scale

	Supraclavicular group (n=58)	Retroclavicular group (n=59)	P-value
Imaging time (min)	1.8 (1.5, 2.0)	2.3 (1.9, 2.6)	0.07
Needling time (min)	5.0 (4.7, 5.4)	6.0 (5.4, 6.6)	0.006
Procedure time (min)	6.8 (6.4, 7.5)	8.3 (7.6, 9.0)	0.005
Pain score during block procedure (NRS, 0–10)	1.6 (1.3, 1.8)	1.8 (1.5, 2.1)	0.19
Duration of sensory blockade (min)	381 (349, 414)	415 (380, 450)	0.16
Duration of motor blockade (min)	432 (394, 471)	507 (469, 544)	0.006

Table 3 Pain-related outcomes. Data are presented as means with 95% confidence interval. NRS, numeric rating scale

	Supraclavicular group (n=58)	Retroclavicular group (n=59)	P-value
Pain score at rest at 2 postoperative hours (NRS, 0–10)	0.4 (0.1, 0.7)	0.4 (0.2, 0.6)	0.95
Pain score at rest at 24 postoperative hours (NRS, 0–10)	1.2 (2.1, 2.7)	1.5 (1.6, 2.4)	0.09
Time to first opioid request (min)	439 (399, 479)	447 (397, 498)	0.80
Total oxycodone consumption at 24 postoperative hours (mg)	10.0 (6.5, 13.5)	7.9 (4.8, 11.0)	0.37
Patient satisfaction (NRS, 0–10)	9.3 (9.0, 9.5)	9.2 (8.9, 9.4)	0.61

plexus block, and not with a traditional infraclavicular approach. We elected to compare with a supraclavicular procedure, as this technique is the gold standard in our institution as the superficial location of the anatomical structures facilitates the identification of the needle and the speed of the

procedure. We are confident that the patients remained blinded throughout, as the arm was maintained in the adducted position for both blocks, and despite a differing probe placement, the needle insertion point was via the supraclavicular fossa in both cases. Another limitation of this study is that the

outcome collector was unmasked. We do not think that this had an impact on the validity of the results, as the person performing the statistics, patients, and all other caregivers were blinded. Finally, it is possible that collecting data from patients at 24 postoperative hours via a diary and a 24 h telephone assessment might have led to recall bias.

In conclusion, ultrasound-guided retroclavicular and supraclavicular brachial plexus block share the same success rates, with identical block characteristics, while providing similar pain relief.

Authors' contributions

Study design: SG, EA.

Study registration: SG.

Patients recruitment: SG, EW.

Manuscript editing and approval: all authors.

Data interpretation: AP, EA.

Statistical analysis: EA.

Declarations of interest

EA has received grants from the Swiss Academy for Anaesthesia Research, Lausanne, Switzerland (50 000 CHF; no grant number attributed), from B. Braun Medical AG (56 100 CHF; no grant number attributed) and from the Swiss National Science Foundation to support his clinical research (353 408 CHF; grant number: 32003B_169974/1). EA has also received an honorarium from B. Braun Medical AG. AP has received honoraria from GE Healthcare for teaching, and consults for B Braun Medical UK and Medaphor. The other authors declare that they have no conflicts of interest.

References

1. Albrecht E, Mermoud J, Fournier N, Kern C, Kirkham KR. A systematic review of ultrasound-guided methods for brachial plexus blockade. *Anaesthesia* 2016; **71**: 213–27
2. Yazer MS, Finlayson RJ, Tran DQ. A randomized comparison between infraclavicular block and targeted intra-cluster injection supraclavicular block. *Reg Anesth Pain Med* 2015; **40**: 11–5
3. Charbonneau J, Fréchette Y, Sansoucy Y, Echave P. The ultrasound-guided retroclavicular block: a prospective feasibility study. *Reg Anesth Pain Med* 2015; **40**: 605–9
4. Hebbard P, Royse C. Ultrasound guided posterior approach to the infraclavicular brachial plexus. *Anaesthesia* 2007; **62**: 539
5. Sutton EM, Bullock WM, Gadsden J. The retroclavicular brachial plexus block: additional advantages. *Reg Anesth Pain Med* 2015; **40**: 733–4
6. Kavrut Ozturk N, Kavakli AS. Comparison of the coracoid and retroclavicular approaches for ultrasound-guided infraclavicular brachial plexus block. *J Anesth* 2017; **31**: 572–8
7. Schulz KF, Altman DG, Moher D. CONSORT 2010 statement: updated guidelines for reporting parallel group randomised trials. *PLoS Med* 2010; **7**: e1000251
8. Macfarlane AJ, Perlas A, Chan V, Brull R. Eight ball, corner pocket ultrasound-guided supraclavicular block: avoiding a scratch. *Reg Anesth Pain Med* 2008; **33**: 502–3. author reply 504
9. Sancheti SF, Uppal V, Sandeski R, Kwofie MK, Szerb JJ. A cadaver study investigating structures encountered by the needle during a retroclavicular approach to infraclavicular brachial plexus block. *Reg Anesth Pain Med* 2018; **43**: 752–5
10. Pianezza A, Salces y Nedeo A, Chaynes P, Bickler PE, Minville V. The emergence level of the musculocutaneous nerve from the brachial plexus: implications for infraclavicular nerve blocks. *Anesth Analg* 2012; **114**: 1131–3

Handling editor: J.G. Hardman